

EXPEDITED REVIEW

Early Experience With Percutaneous Transcatheter Implantation of Heart Valve Prosthesis for the Treatment of End-Stage Inoperable Patients With Calcific Aortic Stenosis

Alain Cribier, MD, FACC,* Hélène Eltchaninoff, MD,* Christophe Tron, MD,* Fabrice Bauer, MD,* Carla Agatiello, MD,* Laurent Sebah, MD,* Assaf Bash, PhD,§ Danielle Nusimovici, MD,§ P. Y. Litzler, MD,† Jean-Paul Bessou, MD,† Martin B. Leon, MD, FACC‡

Rouen, France; New York, New York; and Fort Lee, New Jersey

OBJECTIVES	This study was done to assess the results of percutaneous heart valve (PHV) implantation in non-surgical patients with end-stage calcific aortic stenosis.
BACKGROUND	Replacement of PHV has been shown to be feasible in animals and humans. We developed a PHV composed of three pericardial leaflets inserted within a balloon-expandable stainless steel stent. We report the acute and early follow-up results of the initial six PHV implantations.
METHODS	An anterograde approach was used in all cases. The PHV, crimped over a 22-mm diameter balloon, was advanced through a 24-F sheath from the femoral vein to the aortic valve and delivered by balloon inflation. Clinical, hemodynamic, and echocardiographic outcomes were assessed serially.
RESULTS	All patients were in New York Heart Association functional class IV. The PHV was successfully delivered in five patients. Early migration with subsequent death occurred in one patient who presented with a torn native valve. Acute hemodynamic and angiographic results showed no residual gradient, mild (three patients) or severe (two patients) aortic regurgitation, and patent coronary arteries. On echocardiography, the aortic valve area was increased from $0.5 \pm 0.1 \text{ cm}^2$ to $1.70 \pm 0.03 \text{ cm}^2$ and the aortic regurgitation was paravalvular. Marked and sustained hemodynamic and clinical improvement was observed after successful PHV implants. The first three patients died of a non-cardiac cause at 18, 4, and 2 weeks, respectively, and the other patients are alive at 8 weeks with no signs of heart failure.
CONCLUSIONS	Implantation of the PHV can be achieved in patients with end-stage calcific aortic stenosis and might become an important therapeutic option for patients not amenable to surgical valve replacement. (J Am Coll Cardiol 2004;43:698-703) © 2004 by the American College of Cardiology Foundation

Prolonged life expectancy has resulted in an aging population and, consequently, in an increased number of patients with degenerative calcific aortic stenosis. Surgical aortic valve replacement is the treatment of choice for a vast majority of patients, offering symptomatic relief and improving long-term survival (1,2). However, in a subset of patients, mainly elderly patients with declining overall health status or life-threatening comorbidities, aortic valve replacement is considered either too high risk or is contraindicated. Balloon aortic valvuloplasty has been shown to provide temporary improvement of valvular function and relief of symptoms in this non-surgical population (3,4), but its use is impaired by an unacceptably high mid-term

(within months) frequency of restenosis (5). Given the limited therapeutic options in this subset of patients, there has been interest in the development of a percutaneously delivered bioprosthetic aortic heart valve.

Recent advances in stent and valve technologies have demonstrated that percutaneous valve replacement is feasible in both animals and humans. The integration of a bioprosthetic valve and a stent was first demonstrated by Andersen et al. in 1992 (6) in which a porcine bioprosthesis attached to a wire-based stent was delivered at various aortic sites with satisfactory acute hemodynamic results. Since then, several other investigators have reported the implantation by catheter delivery techniques of prosthetic valves of various designs in animal models (7-11). The first clinical cases of percutaneous valve replacement in congenital heart disease were reported by Bonhoeffer et al. (12,13), who successfully implanted prosthetic heart valves made from bovine jugular vein and mounted onto a platinum-iridium stent and placed in stenotic right ventricle to pulmonary conduits with good immediate and long-term results.

From the Departments of *Cardiology and †Cardiac Surgery, Charles Nicolle Hospital, University of Rouen, Rouen, France; ‡Cardiovascular Research Foundation, Lenox Hill Hospital, New York, New York; and §Percutaneous Valve Technologies, Fort Lee, New Jersey. Drs. Cribier and Leon have stock ownership in Percutaneous Valve Technologies Inc., the company that designed and provided the percutaneous valve used.

Manuscript received October 10, 2003; revised manuscript received November 24, 2003, accepted November 24, 2003.

Abbreviations and Acronyms

PHV = percutaneous heart valve
NYHA = New York Heart Association

We developed an original percutaneous heart valve (PHV) that was initially composed of three bovine pericardial leaflets mounted within a stainless steel balloon-expandable stent (Percutaneous Valve Technologies Inc., Fort Lee, New Jersey) with the goal of treating non-surgical patients with end-stage aortic stenosis. The stent is 14 mm in length and achieves a maximal diameter of 23 mm after full balloon inflation. Extensive *ex-vivo* testing and animal implantation studies have been completed (11), and we reported the successful implantation of this PHV in a patient with end-stage aortic stenosis (14). Since the first case, additional improvements to the PHV device have been made, and confirmatory pre-clinical testing (bench and animal) has been conducted with the goal of supporting further clinical studies. The new PHV is composed of three equine pericardial leaflets mounted within a reinforced stent frame (Fig. 1). Valve durability testing has completed 200 million cycles (5 years). Our early clinical experiences in patients with PHV implantation are reported.

METHODS

Patients. From April 2002 to August 2003, PHV implantation was attempted in six patients, five males and one female, age 75 ± 12 years (range 57 to 91 years) with severe calcific aortic stenosis and multiple comorbidities (Table 1). Each patient had been declined for surgery by cardiac surgeons owing to hemodynamic instability and/or severe comorbidities. Three of these patients were in cardiogenic shock and all were in New York Heart Association (NYHA) functional class IV congestive heart failure. Balloon valvuloplasty had been previously attempted in four cases, but either failed or led to early valve restenosis. Transthoracic and transesophageal echocardiography demonstrated in all cases a heavily calcified aortic valve (bicuspid in Patient 1 and tricuspid in all other cases), with a valve area ≤ 0.6 cm² by the continuity equation, and in all but one patient (Patient 2), a low transvalvular gradient (<50 mm Hg) due to severe left ventricular dysfunction. Moderate to severe aortic regurgitation was present in four patients and mitral regurgitation in five patients. Detailed echocardiographic parameters are shown in Table 2. Only one patient (Patient 6) had associated coronary artery disease (right coronary occlusion at the ostium).

Approval of our institutional ethic committee for compassionate PHV implantation was obtained for each case, and all patients and their closest relatives gave informed consent.

Procedure. Each procedure was performed under local anesthesia and mild sedation. Aspirin (160 mg) and clopidogrel (300 mg) were administered the day before the

procedure. In all cases, the antegrade trans-septal approach was used for PHV implantation, as previously described (14). Briefly, basal hemodynamic parameters, supra-aortic, left ventricular, and coronary angiograms were first obtained. Trans-septal catheterization was performed from the right femoral vein, and heparin 5,000 IU was administered intravenously. A 7-F flotation balloon catheter was used for antegrade crossing of the aortic valve, and a stiff 0.035-inch guide wire was advanced through this catheter to the descending aorta and externalized through the left femoral artery using a catheter snare. The trans-septal puncture site was then dilated with a 10-mm balloon catheter, and a 23-mm balloon catheter advanced from the right femoral vein was used to predilate the native aortic valve. Using a mechanical crimping device, the PHV was securely crimped over a 23- or 22-mm (last four cases) diameter, 30-mm length balloon catheter (Z-Med II, NuMed Inc., Hopkinton, New York). Through a 24-F sheath (Cook, Bjæverskov, Denmark) placed into the right femoral vein, the PHV was advanced over the wire, across the interatrial septum, and within the stenotic native valve.

The following steps of valve implantation are shown in Figure 2. In the antero-posterior view, the valvular calcification and a frozen view of a supra-angiogram were used as markers to position the PHV at the mid-portion of the native aortic valve. In the last four cases, accurate positioning was further facilitated by the use of a 7-F Sones catheter advanced from the left femoral artery over the same guide wire and placed in contact with the distal end of the delivery balloon catheter. The Sones catheter also prevented antegrade dislodgement of the delivery balloon during inflation. Using a 10/90 contrast/saline solution, PHV delivery was obtained by maximal balloon inflation followed by rapid deflation. To improve the precision of PHV implantation, in Patients 3 and 5, rapid cardiac pacing (200 to 220 beats/min) of the right ventricle was undertaken during PHV delivery to decrease aortic blood flow and prevent the risk of PHV migration during balloon inflation. The delivery balloon and the guide wire were withdrawn immediately after PHV delivery. Hemodynamic assessment and supra-



Figure 1. Upper view of the percutaneous heart valve, made of three leaflets of equine pericardium inserted within a stainless steel stent.

Table 1. Clinical Characteristics of the Patients

Patient	Age	Gender	Cardiovascular Comorbidities	Noncardiac Comorbidities
1	57	M	Severe PAD, aorto-bifemoral bypass, recent occlusion of the right limb, subacute leg ischemia	Lung cancer (left lobectomy), silicosis; chronic pancreatitis
2	80	M	Massive aortic regurgitation	Recent stroke (<1 month); chronic renal failure; asbestosis; prostate cancer
3	91	M	Pacemaker for syncopal complete AV block	Cachexia (bedridden >1 month, eschars); very old age (>90 yrs)
4	63	M	—	Evolving rectal adenocarcinoma; severe COPD; chronic renal failure
5	80	F	Hypertension	Polymetastatic (lung and bones) breast cancer with chest radiotherapy; COPD; kyphoscoliosis
6	77	M	Inferior MI (RCA occlusion), previous stroke with left hemispheric sequela; porcelain aorta	Chronic renal failure

AV = atrioventricular; COPD = chronic obstructive pulmonary disease; MI = myocardial infarction; PAD = peripheral artery disease; RCA = right coronary artery.

aortic, left ventricular, and selective coronary angiograms (in the last four patients) were then performed as well as transthoracic and transesophageal echocardiography. The venous puncture sites were closed by manual compression whereas puncture closure devices (Angio-Seal, St. Jude Medical Europe, Zaventem, Belgium) were used to close the arterial entry sites. All patients were closely monitored during follow-up, including clinical assessments and sequential transthoracic echocardiography and Doppler examinations at day 1 and weekly thereafter. The continuity equation was used to evaluate the PHV valve area during follow-up. Post-procedural treatment included aspirin (160 mg) and clopidogrel (75 mg) daily. Subcutaneous low molecular weight heparin (enoxaparin, 40 mg/day) was administered during the hospitalization stay. No oral anticoagulation was given.

Statistical analysis. Comparison of echocardiographic variables before, after PHV implantation, and on follow-up was performed using the nonparametric Wilcoxon rank-sum test. Differences were considered significant at $p < 0.05$. Values are expressed as mean \pm standard deviation.

RESULTS

Immediate results. The PHV was successfully and accurately delivered in the subcoronary position in all but one patient. This patient (Patient 2) was in cardiogenic shock, and had severe aortic stenosis associated with massive aortic regurgitation due to a previous balloon aortic valvuloplasty-induced valve tear. The balloon-PHV assembly was ejected in the ascending aorta at the time of full balloon inflation,

and the patient died shortly thereafter. On autopsy, the valve leaflets were disconnected from the annulus on one-third of its circumference. In all other cases, the PHV remained strongly anchored after delivery within the native valve. No residual gradient was observed on simultaneous aortic and ventricular pressure recordings. Post-implantation supra-aortic angiography revealed mild (three cases) or severe (two cases) aortic regurgitation and patent coronary arteries. Coronary ostia were consistently above the upper margin of the PHV on selective coronary angiography. The PHV function was dramatically improved on post-procedure echocardiographic evaluation (Table 2), with an increase in aortic valve area from $0.49 \pm 0.08 \text{ cm}^2$ to $1.66 \pm 0.13 \text{ cm}^2$ ($p < 0.04$) and a decrease in transvalvular gradient from $38 \pm 11 \text{ mm Hg}$ to $5.6 \pm 3.4 \text{ mm Hg}$ ($p < 0.04$). Aortic regurgitation was paravalvular in all cases. During the procedure, hemodynamic collapse occurred in Patients 2 and 6 after balloon pre-dilation requiring transient external cardiac massage and adrenalin infusion. However, PHV implantation (which, in Patient 6, was performed during electromechanical dissociation and external cardiac massage) could be accomplished and was instantaneously followed by full hemodynamic recovery. No other complications ensued. Mean duration of the procedure was $134 \pm 23 \text{ min}$, and mean fluoroscopy time was $28 \pm 14 \text{ min}$.

Clinical course. The procedure was followed in all cases by dramatic clinical improvement, with immediate and sustained reduction of signs of heart failure. The initial three patients who survived the procedure (Patients 1, 3, and 4) died of non-cardiac complication at 18, 4, and 2 weeks,

Table 2. Echocardiographic Characteristics of the Patients

Patient	Mean Gradient (mm Hg)			AVA (cm ²)			AR (0-4)		EF (%)	
	Pre-	Post-	Follow-Up	Pre-	Post-	Follow-Up	Pre-	Post-	Pre-	Follow-Up
1	35	5	8	0.60	1.82	1.64	0	1	10	22
3	56	4	6	0.50	1.70	1.65	2	3	29	40
4	30	2	4	0.40	1.74	1.70	0	1	28	42
5	38	6	6	0.43	1.52	1.62	1	1	34	53
6	31	11	13	0.52	1.62	1.55	2	3	19	48
Mean \pm SD	38 ± 11	$5.6 \pm 3.4^*$	$7.4 \pm 3.4^*$	0.49 ± 0.08	$1.66 \pm 0.13^*$	$1.63 \pm 0.05^*$			24 ± 9.5	$41 \pm 12^*$

Follow-up obtained at two weeks (Patient 3) and four weeks (Patients 1, 4, 5, and 6). * $p = 0.04$ compared to baseline.

AR = aortic regurgitation; AVA = aortic valve area; EF = left ventricular ejection fraction; Pre- and Post- = pre- and post-implantation of percutaneous heart valve.

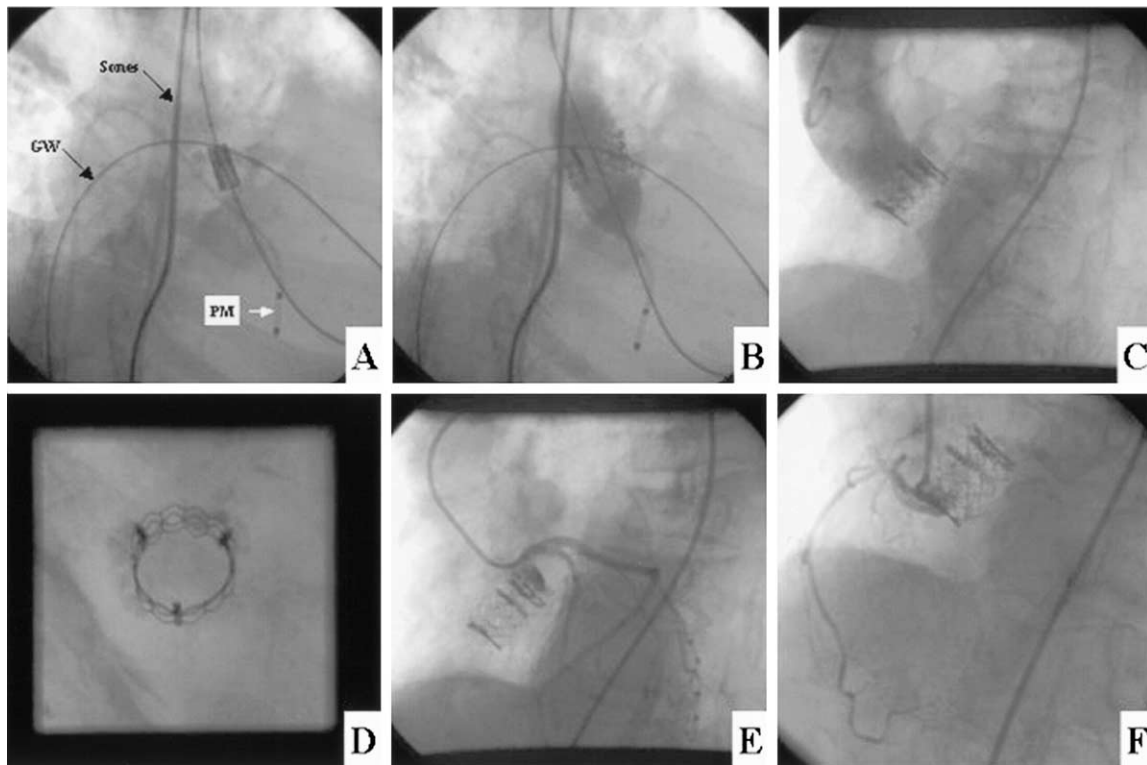


Figure 2. Sequential steps of implantation. (A) The percutaneous valve in position across the native calcific aortic valve before delivery. GW = extra-stiff guide wire; PM = pacemaker lead in the right ventricle for brief period of rapid pacing at the time of balloon inflation; Sones = Sones catheter advanced over the guide wire from the left femoral artery. (B) Balloon inflation for valve delivery. (C) Post-implantation supra-aortic angiogram showing mild aortic regurgitation. (D) Right anterior oblique-cranial view of the valve showing the circular stent frame pushing away the calcified native valve. Selective left (E) and right (F) coronary angiogram post-implantation showing patent coronary ostia.

respectively. Causes of death were complications of leg amputation due to long-standing peripheral vascular disease (Patient 1); an acute abdominal syndrome (Patient 3; this 91-year-old individual had been discharged at day 10 post-procedure with no signs of heart failure); and hemorrhage from rectal carcinoma (Patient 4). The most recent two patients were discharged at days 12 and 15, and they are clinically stable at 8 weeks with no symptoms of heart failure.

Echocardiographic assessment. The PHV function remained normal and unchanged during follow-up with thin and mobile leaflets, no change in transvalvular gradient and valve area, and stable paravalvular aortic regurgitation (Table 2). From baseline to last echocardiographic evaluation, mean left ventricular ejection fraction increased from $24 \pm 9.5\%$ to $41 \pm 12\%$ ($p < 0.04$). The cylindrical PHV frame shape was maintained over time. Only mild transatrial shunting was observed on color flow Doppler studies in all cases.

DISCUSSION

This early experience confirms that a bioprosthetic valve can be implanted percutaneously within the native diseased stenotic aortic valve of patients with end-stage life-threatening calcific aortic stenosis, using standard interventional techniques under local anesthesia. This clinical appli-

cation followed an animal model testing (11) in which the PHV could be delivered at various cardiac sites in the sheep with satisfactory immediate and short-term results. However, implantation within the native aortic valve in the subcoronary position was technically difficult in this model, which varies considerably from humans, with limited space between the coronary ostia and the mitral valve (<6 mm), and a lack of calcific or fibrotic valvular lesion explaining the high rate of early (<15 days) PHV migration.

Implantation of PHV leads to dramatic hemodynamic and clinical improvement with early and mid-term relief of signs of heart failure. The PHV can be accurately delivered in the subcoronary position without impairing the coronary ostia or the mitral valve, and attaches firmly within the diseased native valve. However, pre-procedure valve disruption can impair the anchorage of the PHV, as shown in Patient 2. To avoid impinging of the coronary ostia at the time of PHV delivery, calcification of the native valve on fluoroscopy and the frozen selected frame of the supra-aortic angiogram showing the onset of the left main coronary artery were used as markers. This clinical experience confirmed our postmortem observations that a 14-mm-long stent positioned at the mid-aortic valve does not cover the coronary ostia.

The anterograde trans-septal approach that was used in all cases has several advantages over the more commonly

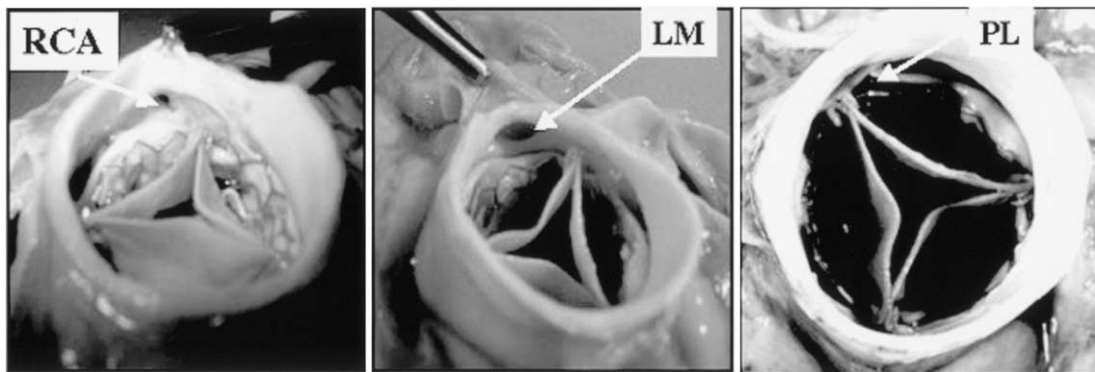


Figure 3. Postmortem findings in Patient 3 (upper views). (Left to right) Right coronary (RCA) ostium (arrow); left coronary (LM) ostium (arrow); and free space between the percutaneous valve and the native valve confirming the mechanism of the paravalvular leak (PL).

used retrograde approach to reach the aortic valve. This route allows percutaneous insertion of the PHV through a 24-F sheath in the femoral vein under local anesthesia, eliminates the risk of arterial thrombosis, dissection, or rupture, and offers more predictable valve delivery since the PHV crosses the less diseased myocardial surface of the aortic leaflets and is coincident with the direction of blood flow. However, special attention must be given at each step of the procedure to maintain a large guide wire loop inside the left ventricle so as to avoid traction on the anterior mitral valve leaflet with subsequent severe mitral regurgitation and hemodynamic collapse. This complication occurred in two patients of this series when the wire was incidentally straightened from the mitral valve to the aortic valve.

A brief period of rapid (200 to 220 beats/min) cardiac pacing causes sufficient impairment of cardiac output during PHV delivery to facilitate precise positioning of the device. This technique, previously used in our center in several balloon aortic valvuloplasty procedures, leads to optimal stabilization of the inflated balloon across the aortic valve. The 10-mm balloon used to dilate the interatrial septum did not create significant residual shunting as confirmed by echocardiography and Doppler imaging. However, in patients with undiseased femoral arteries of suitable size for insertion of a 24-F sheath, the more familiar retrograde aortic approach might be faster and easier to manage for some interventional operators. Furthermore, it would avoid the potential risks of trans-septal catheterization and mitral valve crossing-induced mitral regurgitation and subsequent hemodynamic collapse.

An aortic orifice valve area averaging 1.7 cm² with minimal trans-PHV gradient was instantaneously obtained in all successful cases after PHV implantation. This represents a >3-fold improvement compared with baseline valve areas and was consistently associated with a striking early improvement of left ventricular function and subsequent clinical benefit. The results after PHV implantation are significantly better than those obtained after balloon aortic valvuloplasty, which rarely provides an increase in valve area above 0.8 cm² (3,4). Of note, even in Patient 1, who had no myocardial contractility reserve, and in whom left ventric-

ular ejection fraction remained severely impaired (20%), PHV implantation was followed by marked relief of signs of heart failure. Although ex-vivo studies indicate several-year valve durability, the stability of PHV function over time requires careful assessment and meticulous long-term patient follow-up. However, in this selected population of dying patients in whom severe aortic stenosis is associated with multiple potentially fatal comorbidities, prolonged survival is unlikely, as shown by the post-procedure early deaths from non-cardiac cause in three of the patients.

Paravalvular aortic regurgitation was noted in all patients post-PHV implantation. Echocardiography indicated that there might be imperfect apposition of the PHV stent frame against the diseased native valvular structures at the site of calcific nodules. This was confirmed on postmortem observation in Patient 3 (Fig. 3). Although paravalvular aortic regurgitation did not blunt the early improvement in left ventricular function and clinical status after relief of the aortic valve blockage, severe paravalvular aortic regurgitation might impair long-term clinical outcomes after PHV implantation. Larger maximal stent diameters and other improvements in stent design might decrease the incidence and severity of paravalvular aortic regurgitation in the future.

Because the PHV is a bioprosthetic valve inserted within a stainless steel stent, the anticoagulant regimen was limited to antiplatelet therapy (aspirin and clopidogrel), without long-term oral direct thrombin inhibitors. Prophylactic anticoagulation with intravenous heparin in the first two cases, or low molecular weight heparin in the next cases, was added only during the hospital convalescent period.

An ongoing pilot clinical trial in our center (I-REVIVE study) will allow further refinement of the technique and assessment of both short- and long-term clinical outcomes. Once the operator technique achieves consistent predictable results and beneficial long-term clinical outcomes can be demonstrated, pivotal multicenter clinical trials will be required to determine the role of this promising new therapeutic approach for patients with end-stage calcific aortic stenosis that is not amenable by surgical valve replacement.

Acknowledgments

The authors thank the entire staff of Percutaneous Valve Technologies Inc., Fort Lee, New Jersey: Stanton Rowe, Stanley Rabinovitch, Directors; Elsa Abruzzo, Research Coordinator; Benjamin Spencer and the whole group of engineers; and Raphael Amor, for their support in the research program and in the development of the device. We also thank Gerard Pontier for his help in the collection of data and the presentation of tables and figures, and the entire group of physicians, nurses, and technicians of the Department of Cardiology, Charles Nicolle Hospital, Rouen, for their help and dedication.

Reprint requests and correspondence to: Dr. Alain Cribier, Service de Cardiologie, Hôpital Charles Nicolle, 1 rue de Germont, 76 000, Rouen, France. E-mail: Alain.Cribier@chu-rouen.fr.

REFERENCES

1. Kvidal P, Bergström R, Hörte L-G, Ståhle E. Observed and relative survival after aortic valve replacement. *J Am Coll Cardiol* 2000;35:747–56.
2. Culliford AT, Galloway AC, Colvin SB, et al. Aortic valve replacement for aortic stenosis in persons aged 80 years and over. *Am J Cardiol* 1991;67:1256–60.
3. McKay RG. The Mansfield Scientific Aortic Valvuloplasty Registry: overview of acute hemodynamic results and procedural complications. *J Am Coll Cardiol* 1991;17:189–92.
4. Cribier A, Savin S, Berland J, et al. Percutaneous transluminal balloon valvuloplasty of adult aortic stenosis: report of 92 cases. *J Am Coll Cardiol* 1987;9:381–6.
5. Block P, Palacios IF. Clinical and hemodynamic follow-up after percutaneous aortic valvuloplasty in the elderly. *Am J Cardiol* 1988;62:760–3.
6. Andersen HR, Knudsen LL, Hasenkam JM. Transluminal implantation of artificial heart valves: description of a new expandable aortic valve and initial results with implantation by catheter techniques in closed chest pigs. *Eur Heart J* 1992;13:704–8.
7. Bonhoeffer P, Boudjemline Y, Saliba Z, et al. Transcatheter implantation of a bovine valve in pulmonary position: a lamb study. *Circulation* 2000;102:813–6.
8. Boudjemline Y, Bonhoeffer P. Steps toward percutaneous aortic valve replacement. *Circulation* 2000;105:775–6.
9. Boudjemline Y, Bonhoeffer P. Percutaneous implantation of a valve in the descending aorta in lambs. *Eur Heart J* 2002;23:1045–9.
10. Sochman J, Peregrin JH, Pavnick D, Timmermans H, Rosh J. Percutaneous transcatheter aortic disc valve prosthesis implantation: a feasibility study. *Cardiovasc Intervent Radiol* 2000;23:384–8.
11. Cribier A, Eltchaninoff H, Borenstein N, et al. Transcatheter implantation of balloon expandable prosthetic heart valves: early results in an animal model (abstr). *Circulation* 2001;104 Suppl II:II552.
12. Bonhoeffer P, Boudjemline Y, Saliba Z, et al. Percutaneous replacement of pulmonary valve in a right-ventricle to pulmonary artery conduit with valve dysfunction. *Lancet* 2000;356:1403–5.
13. Bonhoeffer P, Boudjemline Y, Qureshi SA, et al. Percutaneous insertion of the pulmonary valve. *J Am Coll Cardiol* 2002;39:1664–9.
14. Cribier A, Eltchaninoff H, Bash A, et al. Percutaneous transcatheter implantation of an aortic valve prosthesis for calcific aortic stenosis: first human description. *Circulation* 2002;106:3006–8.